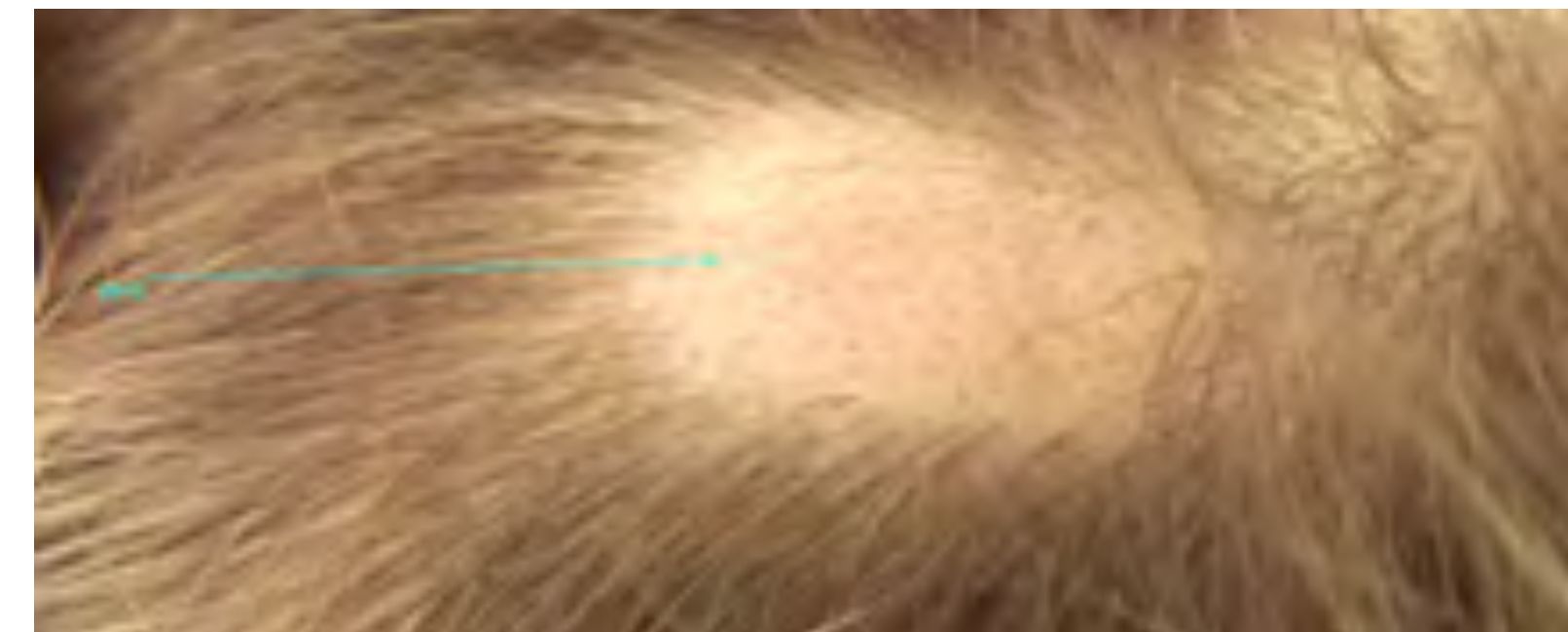



ALOPECIA AREATA

Alopecia areata is a harmless, non-infectious, inflammatory loss of hair that can affect adults and children of both genders at any time to varying degrees.

The trigger is unknown, but it is believed that this is an autoimmune disease with a genetic predisposition: 20–25 per cent of all affected individuals have a “related” autoimmune disease (e.g. Type I diabetes mellitus, Hashimoto thyroiditis, or vitiligo).



Diagnosis of alopecia areata

A dermatoscope is becoming increasingly more important in the diagnosis of alopecia areata. Performing a biopsy on the scalp of an already traumatised patient is not well tolerated! Furthermore, a dermatoscope also serves the therapeutic course and is suitable for distinguishing alopecia areata from scarring alopecia or alopecia mechanica.

When assessing a hairless area, one usually sees short vellus hair, curved “comma hair”, black points, empty follicular ostia, and yellow, punctate areas that occasionally enclose black points.

A dense lymphocytic perifollicular infiltrate with focal follicle infiltration can be seen in histological examinations. Interferon-gamma and interleukin 2 as well as interleukin-15 receptor B are involved in the pathogenesis. Only hair follicles in the growth phase (anagen phase) are affected. The infiltrate damages the hair follicle, thereby leading to dystrophy of the hair shaft and ultimately breakage, incomplete keratinisation, or hair loss and reduction to miniature follicles. The cyclic renewal of the hair follicle (catagen/telogen) is maintained, thereby leading to regression of the infiltrate. The new anagen phase then leads to either a renewed attack of infiltrate or spontaneous hair growth. Spontaneous regrowth usually occurs in the centre of the bald spot and spreads out to the periphery.

The prognosis depends on the extent and the number of bald areas as well as the duration. As a rule of thumb, within the first six months, approximately 30% of alopecia areata patients demonstrate renewed growth or complete healing.

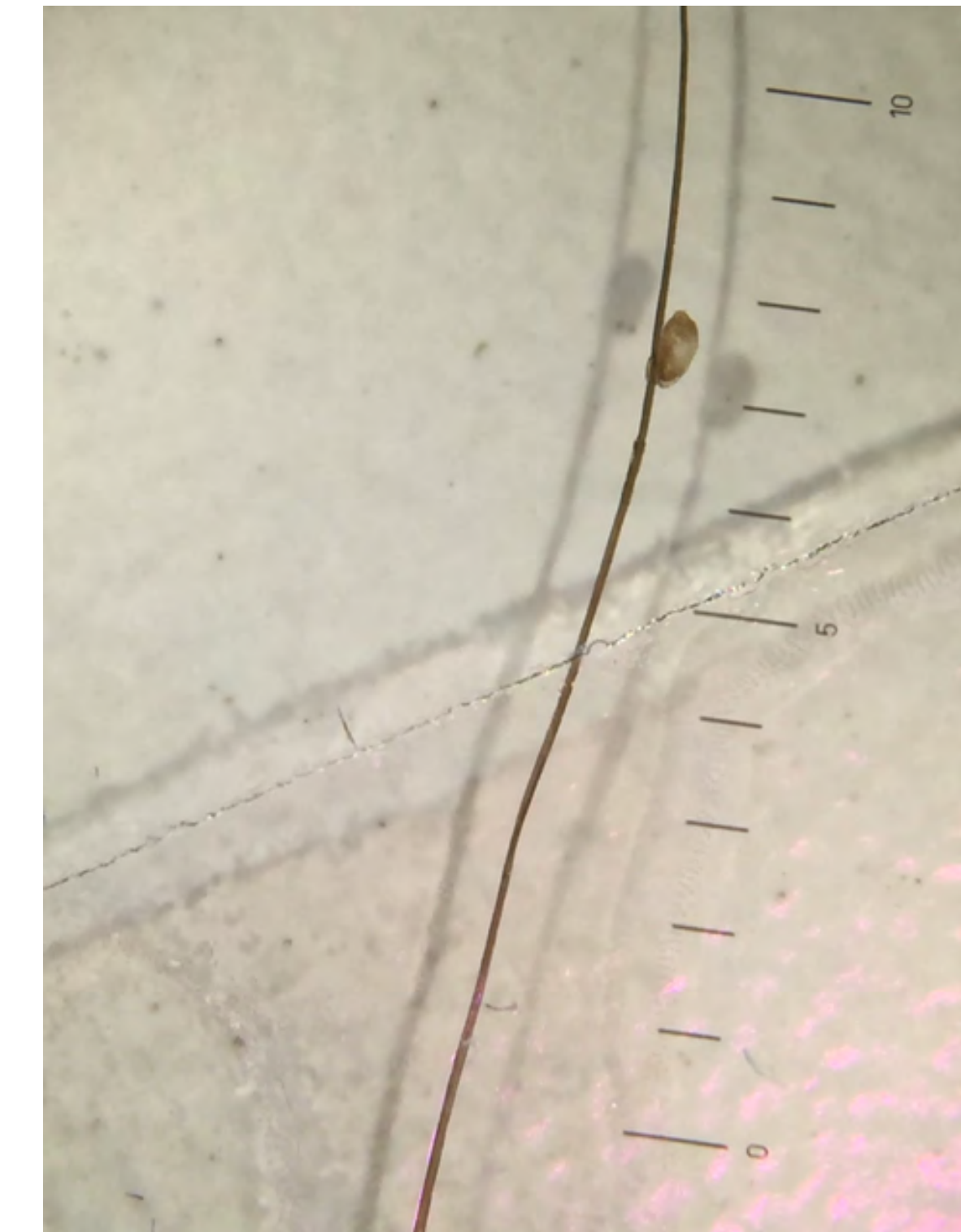
HEAD LICE

Pediculus humanus capitis

Head lice are parasitic insects that live close to the human scalp. They feed on blood drawn from the scalp. Their saliva suppresses blood clotting and acts immunological. By moving from hair to hair with the help of their claws they can quickly move from one head to the next.

Females produce about 100 to 300 eggs in their life, even without male fertilization. The eggs are glued near the base of a host hair shaft and the lice nymphs, with about 1-2mm in size, hatch after 7 to 8 days. Head lice become sexually mature after 9 to 12 days and are then about 3 mm long. In best possible conditions head lice have a live cycle of 20-30 days.

Children are more frequently infested than adults and girls more frequently than boys. The frequency of head lice infestation in Central and Northern Europe in childhood is between 2 and 20%, in developing countries however up to 60 %. Head lice infestations are especially common in supervised facilities, kindergartens or schools.



Symptoms

The immune system recognises lice saliva as a foreign substance and reacts with an immune reaction of the delayed type. In an initial infection, symptoms occur after 4 to 6 weeks. You can typically find numerous tiny red, strongly itching papules, especially in places with very high hair density (at the back of the head and above the ears). Scratched areas pose a potential risk for certain viruses (streptococcus, staphylococcus) which are often accompanied by swollen lymph nodes.

Studies have shown that head lice can transmit *Rickettsia prowazekii* (a bacillus bacterium that is the cause of epidemic typhus) and *Bartonella quintana* (causative agent of trench fever). These dangerous bacteria are however rather seldom in Europe.

Conventional Diagnosis

Often, the disease is discovered if a louse falls from the head while brushing the hair, if a child is scratching its head or if you see a louse on the head. Generally, a diagnosis is not quite as simple, as in Europe most infected hosts have less than ten lice. Depending on their development stage, head lice are difficult to see, as they are tiny and almost translucent or they have a similar colour as the hair. A clinical examination has to be very accurate and is most promising in the neck. Empty eggshells (nits) can be easily seen as oval white structures; the developable, grey-brown eggs however are rather nondescript. Compared to dandruff, eggs cannot be combed out easily. Lice are can be best detected by wet combing.

A diagnosis can often be made with a microscopic examination of hair or with a direct examination of the scalp with the help of a dermatoscope. Contact your doctor to discuss this type of examination.

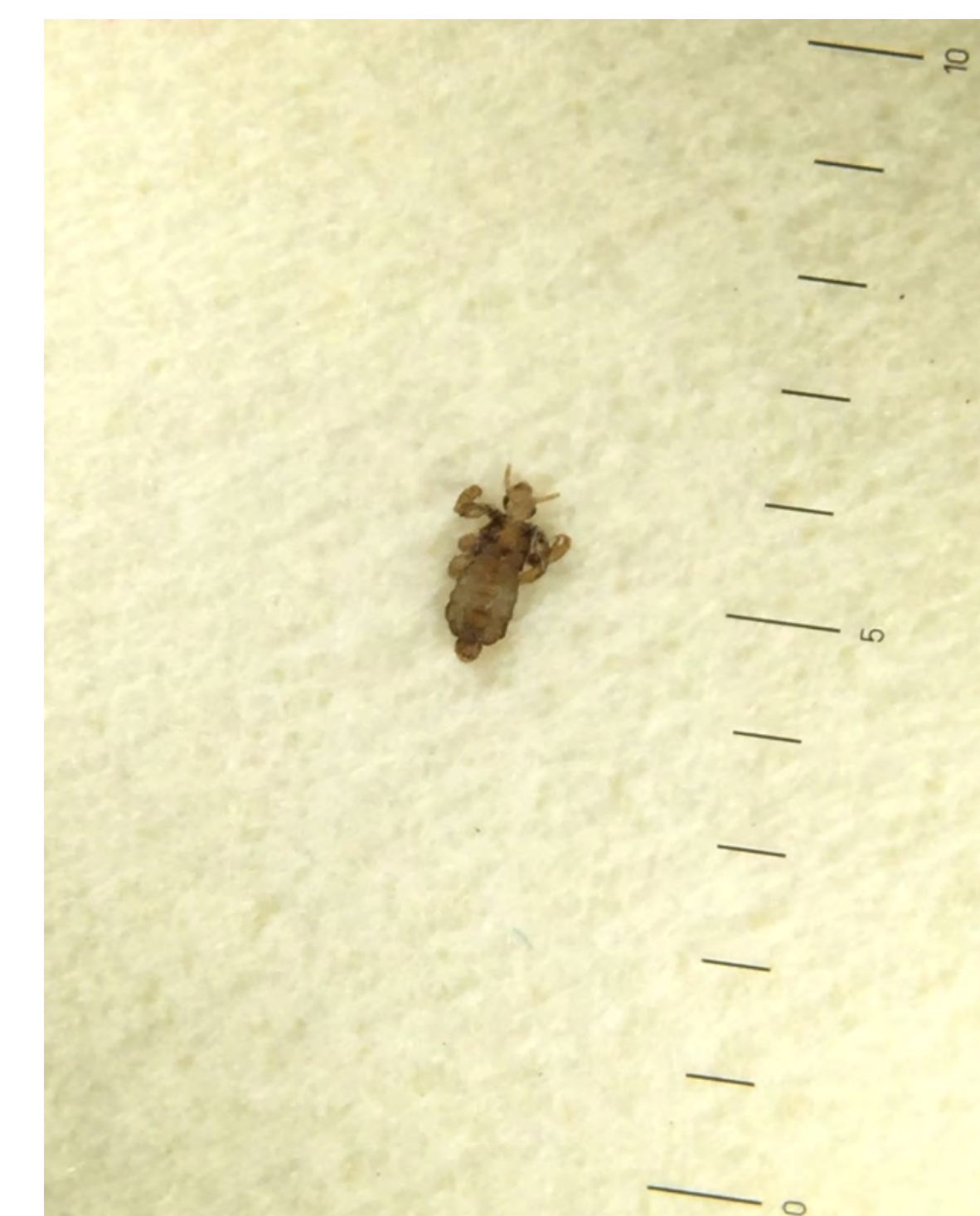Diagnosis of Lice and Nits using a Dermatoscope

The dermatoscope is gaining increasing importance in the diagnosis of parasitic diseases. Juvenile lice are so tiny that they cannot be seen with the naked eye. With the help of a dermatoscope however, they can be clearly identified. Differentiating between resisting dandruff, hair spray residues and eggs is made easier by the precise magnification.

Using a dermatoscope also saves time in the daily routine of a busy practice, as you do not have to remove hair and take it to a microscope to examine it. The examination can be directly done on the scalp of the patient.

A non-contact dermatoscope, such as the [NC2 from HEINE](#) may be used, which offers an illuminated magnification, without having to touch the patient's skin. Nosocomial infections in subsequent examinations can therefore be avoided.

Traditional contact dermatoscopes may also be used. Please do not forget to disinfect the contact plate before and after the examination by wipe cleaning.





ITCH MITES

Sarcoptes scabiei

Scabies is caused by a parasitic arthropod, the itch mite (*Sarcoptes scabiei*). Itch mites belong to the class of arachnids with 8 legs. Similar to lice, scabies spreads primarily where many people live closely together. Therefore, retirement and nursing homes, but also kindergartens, schools and even hospitals are most frequently affected. Scabies is spread from humans to humans through close skin-to-skin contact. The incubation period for scabies is about 3-6 weeks. With an intact immune system and with good hygienic conditions, the immune reaction of the body keeps the number of mites at a relatively low level. After infestation, the 0.3 to 0.5 mm long females burrow just beneath the surface of the skin and deposit their eggs in the so-called burrows. Males remain on the surface of the skin to find a female. The lifespan of a female mite living in the skin is about 60 days. Off a person, itch mites usually do not survive more than 48 hours, as they feed on human skin cells and lymphatic fluids.

Clinic

Itch mites prefer skin areas with a higher body temperature. Therefore, they most commonly occur between fingers, on wrists, genitals, armpits and belly buttons. In small children or in case of a serious clinical picture, the scabies *norvegica*, mites may also burrow into the neck and/or head. In the first weeks, the infestation may be asymptomatic and may lead to strong itching at night due to an immune reaction against mite products (decayed mite components, eggs, faeces).

Diagnosis with the help of dermatoscopy

Very important for the diagnosis are the anamnesis (especially nocturnal itching, possible infestation of close roommates or colleagues) and the examination of the typical preferred localisations such as between fingers and on genitals. Scratching will show little red bumps or sometimes even red burrow lines, which look like long-stretched tracks. In former days, a biopsy was necessary in order to diagnose an infestation.

Further developments in dermatoscopy (e.g. improved image sharpness and magnification) have made the diagnosis of scabies a lot easier. In a diagnosis with the help of a dermatoscope the itch mites can be found and seen a lot easier and a long search is not necessary anymore. Usually, they can be found on the edge of a bump or a burrow. The head and the breast of the mite appear typically as dark triangle-shaped areas. The abdomen is transparent and therefore hardly visible.

Therapy

Permethrin is used to treat scabies in adults and children for external application. Alternatively benzyl benzoate can be used. Oral ivermectin is also used occasionally. Usually, a short-term use of a mild steroid cream is recommended.

During the treatment, all objects that are also used by other persons should be cleaned and disinfected in order to prevent transmission of scabies. Clothes and bed linen should be washed at a temperature of at least 60° C. Alternatively, place the clothes in a hermetically sealed plastic bag and freeze it for a few days.

For further information please use the [Scabies Diagnostic information](#).

Sources

[Videodermoscopy compared to reflectance confocal microscopy for the diagnosis of scabies](#). Cinotti E, Labeille B, Cambazard F, Biron AC, Chol C, Leclercq A, Jaffelin C, Perrot JL. See comment in PubMed Commons below | Eur Acad Dermatol Venereol. 2016 Sep;30(9):1573-7. doi: 10.1111/jdv.13676. Epub 2016 May 11

[Diagnosis of trombiculosis by videodermatoscopy](#). Nasca MR, Lacarrubba F, Micali G. Emerg Infect Dis. 2014 Jun;20(6):1059-60. doi: 10.3201/eid2006.130767.

[Dermoscopy aids the diagnosis of crusted scabies in an erythrodermic patient](#). Bollea Garlatti LA, Torre AC, Bollea Garlatti ML, Galimberti RL, Argenziano G. J Am Acad Dermatol. 2015 Sep;73(3):e93-5. doi: 10.1016/j.jaad.2015.04.061



MORBUS GROVER

Transient acantholytic dermatosis

Grover's disease is a benign papular skin disease characterised histologically by acantholysis. Grover's disease is mainly seen in older, fair-skinned males, of the sebostatic skin type. Suspected triggers include local irritations, sunlight, xerosis, increased sweating and heat.

Skin disorders usually heal within weeks to months; sometimes it can however take years to clear up. Disseminated, succulent, non-confluent papules and occasionally even papulovesicles with keratotic or partly crusty surfaces can be found on the chest, neck and upper back. Itching can be severe.

Histological Diagnosis

In a histological examination you can see a circumscribed acantholysis with suprabasal or subcorneal gap formations, often accompanied by a spongiosis and a dyskeratosis. They can be categorised into different types, which resemble 4 other skin diseases (Darier disease, Spongiotic Dermatitis, Hailey-Hailey disease and Pemphigus).

Dermatoscopic Diagnosis

Disseminated, single reddish-yellowish papules and papulovesicles partly with hyperkeratosis occur primarily on the trunk. In dermatoscopy hyperkeratosis can be recognised well due to the whitish, yellowish firmly attached scale. One look through the dermatoscope is often enough to differentiate between other itching skin diseases, such as excoriation eczema that also occurs often in older men.

Therapy

Locally you can use nourishing lotions, such as Lotio alba. Short-term treatment with creams containing cortisone may also be considered.

Additionally, an internal therapy with antihistamines over a period of 1 to 2 weeks has proven to be successful. Agonising pruritus is treated with PUVA therapy or UVB/UVA light therapy. Glucocorticosteroids are available systemically.

There are also reports about therapy attempts with vitamin A acid derivatives such as Isotretinoin in therapy-resistant cases.

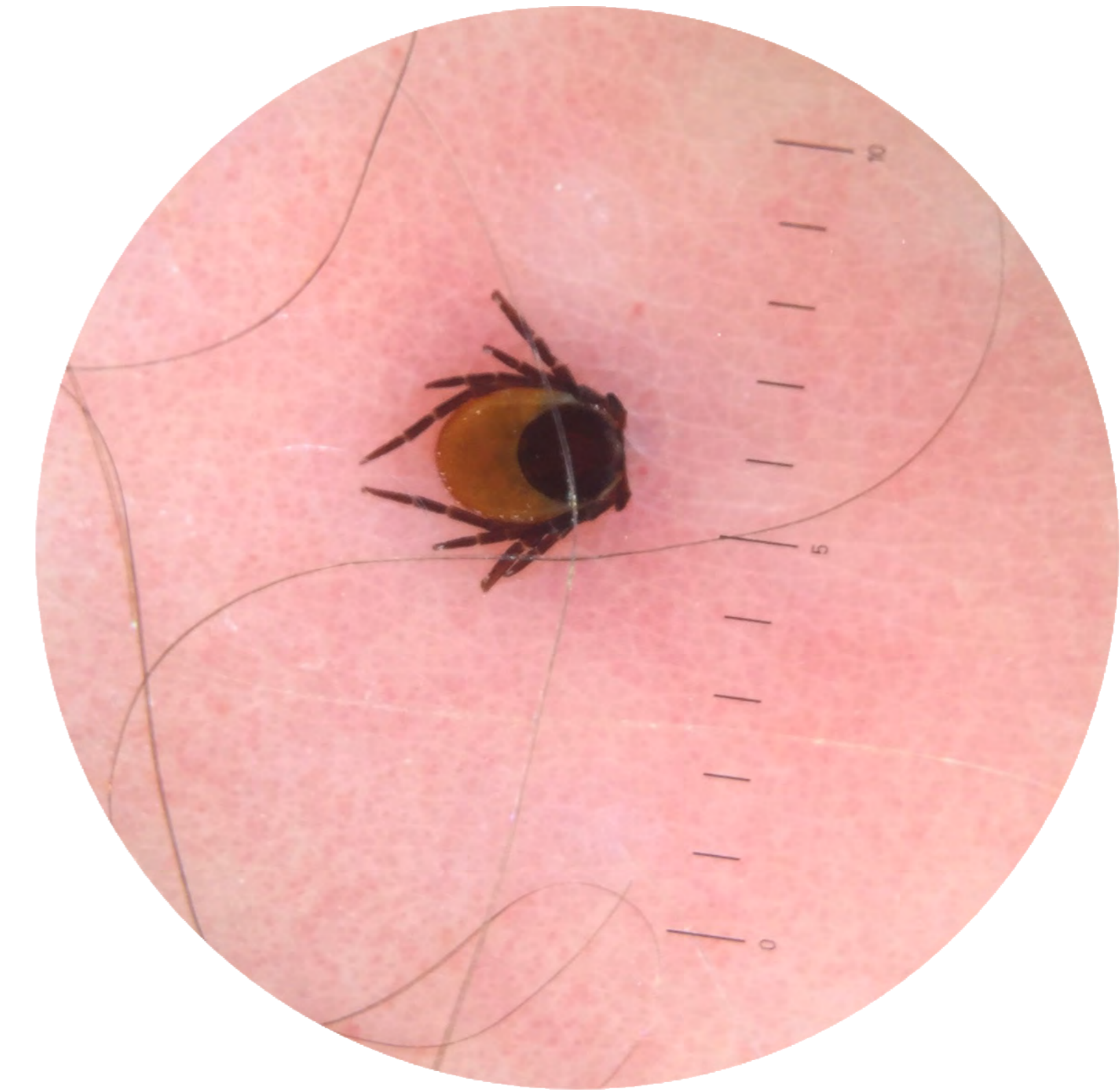
TICKS AND LYME BORRELIOSIS

Epidemiology

Ticks are widespread and can be found primarily on grass, bushes and leaves. Waiting for a suitable host, they attach themselves on clothes or directly on the skin as soon as the opportunity presents itself. About 20 tick species are known in Germany, whereas the Castor Bean tick (*Ixodes ricinus*) harms human beings most frequently. While ticks only posed a danger during the summer months in the past, as they used to be hibernating during the winter months, they have since become active all year round due to the mild winters.

Tick bites itself would not be problematic, but ticks are regularly carriers of bacteria (which cause Borreliosis) and viruses (the causative agent of spring-summer meningoencephalitis, FSME). Very seldom, they may also transmit other diseases such as Babesiosis, Ehrlichiosis, Rickettsiosis or Neoehrlichiosis.

According to the Robert Koch Institute 10 % to 35 % of ticks are infected with borrelia. As the carriers are found in the intestine of the Castor Bean ticks, the tick must draw blood from its host for about 12 hours until they are transmitted via the saliva to the host. In Germany, about 2 % to 6 % of the people who were bitten by a tick are infected with borrelia. In much rarer cases, ticks are infected with FSME viruses. In the German FSME risk areas about 0.1 % to 5 % carry the virus – especially in Bavaria and Baden-Wuerttemberg.



Tick

Clinic and diagnosis

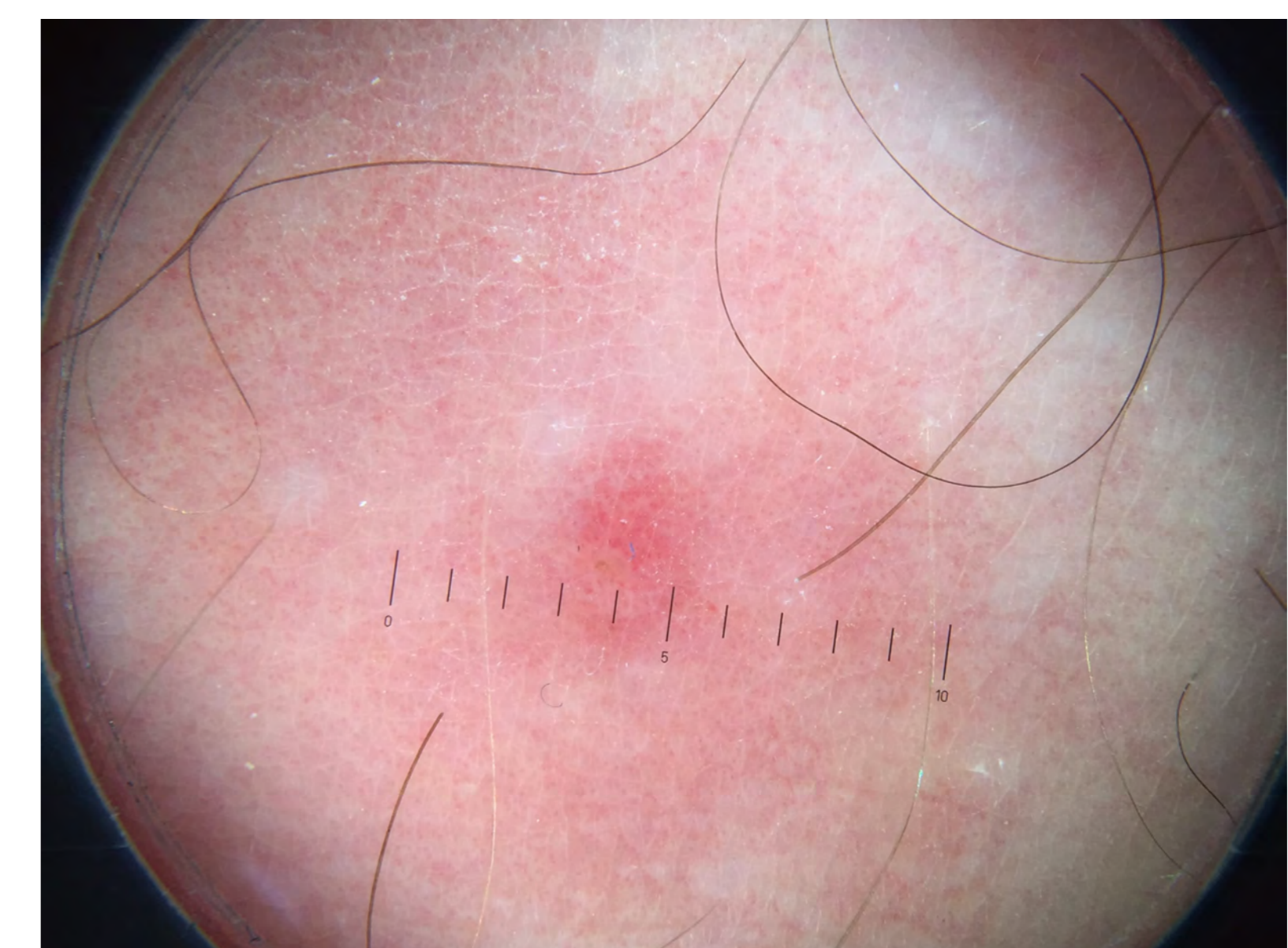How can an examination with the dermatoscope help?

A tick that is embedded in the skin must be removed as soon as possible, either by yourself or by a doctor.

But sometimes this is not quite as easy: On the one hand, irritated small fibromas, which are usually found on places that are also preferred by ticks, such as neck, axillary or the groin region, can sometimes hardly be distinguished from ticks. In this case, a dermatological examination at the doctor can help finding the right diagnosis.

On the other hand, the tick's mouth parts may be left behind in the skin. This in itself is not dangerous with regard to the communicable diseases transmitted by ticks, but may result in a strong localised infection that may require local therapy. With the help of a dermatoscope, a doctor can remove these parts using splinter tweezers or a small punch.

After removing the tick, the bite spot has to be monitored for a few weeks. It is possible to send your tick to a laboratory for testing to see if they carry borrelia. This approach however is a controversial issue. When blood samples are taken for a determination of antibodies it should be understood, that it takes a certain time to verify them.



Tick bite spot

Therefore, above all the clinical picture helps to make a diagnosis: Lyme disease first manifests itself almost always as a local infection of the skin, the erythema migrans. The classic sign of an early local infection is a circular, outwardly expanding red rash of several centimeters which occurs at the site of the tick bite. Due to the mild symptoms, this early skin disease may not be seen or noticed, e.g. on the scalp of children.

Haematogenous dissemination may occur and usually goes along with an influenza-like clinical picture. Other organs may also be affected, typically the nervous system and the joints.

References:

- ✦ AWMF Guideline of the German Society of Dermatology, Working Group on Dermatologic Infectiology
- ✦ German Borreliosis Society